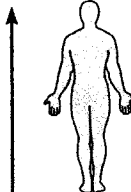
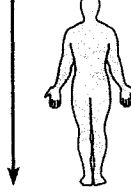


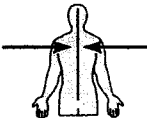
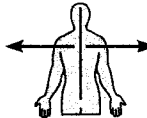
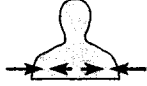
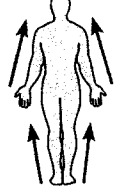
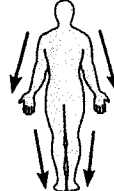
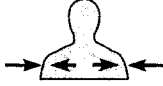



TABLE 1.1

Term	Definition	Example
Superior (cranial)	Toward the head end or upper part of a structure or the body; above	 The head is superior to the abdomen
Inferior (caudal)	Away from the head end or toward the lower part of a structure or the body; below	 The navel is inferior to the chin
Anterior (ventral)*	Toward or at the front of the body; in front of	 The breastbone is anterior to the spine
Posterior (dorsal)*	Toward or at the back of the body; behind	 The heart is posterior to the breastbone
Medial	Toward or at the midline of the body; on the inner side of	 The heart is medial to the arm
Lateral	Away from the midline of the body; on the outer side of	 The arms are lateral to the chest
Intermediate	Between a more medial and a more lateral structure	 The collarbone is intermediate between the breastbone and shoulder
Proximal	Closer to the origin of the body part or the point of attachment of a limb to the body trunk	 The elbow is proximal to the wrist
Distal	Farther from the origin of a body part or the point of attachment of a limb to the body trunk	 The knee is distal to the thigh
Superficial (external)	Toward or at the body surface	 The skin is superficial to the skeletal muscles
Deep (internal)	Away from the body surface; more internal	 The lungs are deep to the skin

*Whereas the terms *ventral* and *anterior* are synonymous in humans, this is not the case in four-legged animals. *Ventral* specifically refers to the "belly" of a vertebrate animal and thus is the inferior surface of four-legged animals. Likewise, although the dorsal and posterior surfaces are the same in humans, the term *dorsal* specifically refers to an animal's back. Thus, the dorsal surface of four-legged animals is their superior surface.

Abdominopelvic Regions

Right hypochondriac:
Upper Right

Umbilical:
Navel

Left hypochondriac:
Upper left

Right lumbar:
Middle right

Epigastric:
Above navel area

Left lumbar
Middle left

Right Iliac or Inguinal:
Lower right

Hypogastric:
Below navel

Left Iliac or Inguinal:
Lower left

A simpler scheme is based on quadrants:

RUQ
LUQ

RLQ
LLQ